

*THIS IS THE BASIS FOR A TALK GIVEN AT THE INTL HOOF SUMMIT IN CINCINATI IN FEBRUARY, 2005.
A VERSION OF THIS PAPER APPEARED IN THE EUROPEAN FARRIER'S JOURNAL (ISSUE #114, 2005), AND A
SUMMARIZED VERSION APPEARED IN THE AMERICAN FARRIER'S JOURNAL (JUNE/JULY 2005).*

HOOF AND BONE MORPHOLOGY OF THE EQUINE DIGIT: CHALLENGES TO SOME COMMON BELIEFS

John J. Craig, Phd, and Monique F. Craig, BSCE
EponaTech, P.O. Box 361, Creston, CA 93432
john@eponatech.com, monique@eponatech.com

Many prevalent notions, so often cited in books and articles regarding the hoof and the bone placement within, should at best be considered 'rules of thumb'. In most cases, one sees that they represent only an approximation of the situation. A farrier, in the field, has many things to be concerned with, and being guided by these approximations is not unreasonable. But given today's digital cameras, digital radiograph systems, and computer measurement software, we can and should take a closer look. When we take this closer look, we find that there are obvious trends to the data. Whereas it seems to be human nature to expect that things are "split 50-50" or are "aligned in parallel" or "align in a straight line", the reality of biological systems is that small-to-moderate asymmetries are present.

Introduction

Common practice when discussing the morphology of the equine digit is to relate it's morphology to an ideal form. But where does this ideal form come from, and can it be described quantitatively?

No quantitative assessment is regularly made of the hoof capsule or the boney column within it. Our field has been hurt by the lack of such quantification, leading to a reliance on beliefs that have been promoted through a long history of developments. A recently introduced technique¹ offers a standardized method by which exact measurements can be quickly made of the digit's anatomical components using radiographs and photographs.

In this paper, we measure from dozens to hundreds of images of the equine foot and lower limb and present quantitative results. We relate these results to several more-or-less well-established beliefs concerning the actual or ideal desired morphology of the hoof and bones.

Materials and Methods

A large mixed-breed group of horses was used as the basis of the studies reported in this paper. Most of the horses were digitally photographed, and many were radiographed as well. Depending on the particular aspect of morphology we are investigating, either photographs or radiographs were used to make the measurements. Our reports indicate varying numbers of images used in each of our 7 studies depending on how many of the particular images required were available from the group. For one of the studies (Study #6), dissection of cadaver legs was used, and this was drawn from another mixed breed group of horses. The details of each of the seven studies presented will be given within each subsection of this report.

The horses measured were for the most part sound. We did not include any "obviously lame" horses, but otherwise, used data from all available horses. We believe using subjective lameness criteria to exclude subjects from a study can skew data, so we chose to use all the data available, only excluding cases that were obviously and seriously lame. The population contained horses maintained by various farriers employing various shoeing techniques. As always, there is a great variation in the horse –

we believe that using a large enough sample allows trends to become noticeable.

The Metron equine hoof conformation software system^a was used to make all of the measurements in the photographs and radiographs. This system makes use of scale markers and can compensate for the magnification inherent in radiographs¹.

While most of the measurements we will make are fairly obvious, we feel it is helpful here to explain the details of how we assign geometry to the bones in order to measure the rotational positions of the coffin and pastern joints.

A central method used in our analysis of the latero-medial radiograph is the fitting of a circle to the distal ends of the first two phalanges, P1 and P2, and taking the center of those circles to represent the center of articulation (COA) of the corresponding joint. An earlier publication² reports on experiments performed to validate this assumption. In that study, we compared the experimentally located center of articulation of the coffin joint with the location as would be found in our method of picking points on an image of a latero-medial radiograph, and found a good correlation.

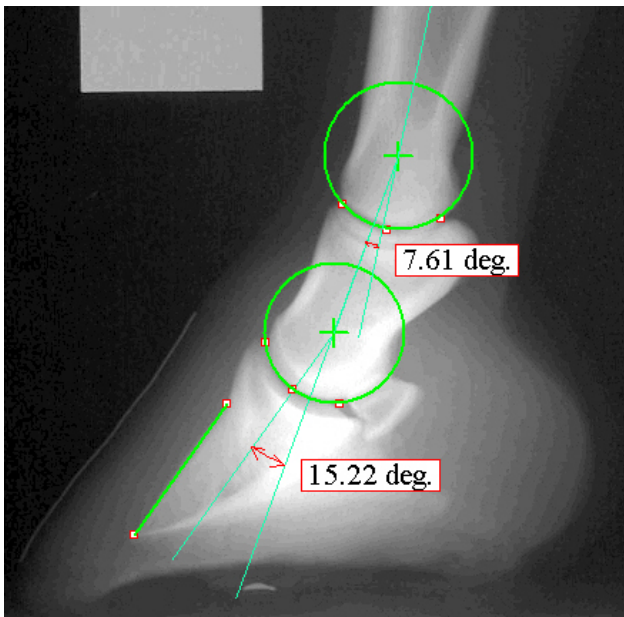


Figure 1: Definition of the coffin-joint angle and the pastern-joint angle.

We propose an important use for the centers of articulation of the coffin and pastern joints: these points are central to establishing a well-defined way to measure the angulations of the bones in the equine digit. Such a technique offers a reliable way for practitioners to communicate regarding conformation of the equine digit.

Our method defines a precise way to measure the rotational position of the coffin and pastern joints as seen in lateral radiographs. In figure 1 we show these joint-angle values. To quantify the coffin-joint angle, construct a line from the rotation center associated with the coffin joint extending down towards the sole and parallel to a reference orientation defined on the dorsal aspect of P3. The value of the coffin-joint angle is the geometric angle formed between this constructed line, and the line defined by connecting the two rotation centers. In the example shown in figure 1, this value is 15.22 degrees. The positive sense is defined such that a positive rotation of the coffin-joint makes the major axis of P2 become more upright in the image.

To quantify the pastern-joint angle, construct a line that connects the two rotation centers. The value of the pastern-joint angle is the geometric angle formed between this constructed line and the line representing the 'centerline of P1'. In the example of figure 1, this value is 7.61 degrees. The positive sense is defined such that a positive rotation of the pastern-joint makes the axis of P1 become more upright in the image.

Results

We present the results of 7 individual studies of the hoof and bone morphology in the following sections.

Study #1. Medial-Lateral ‘Balance’ from the Solar Aspect

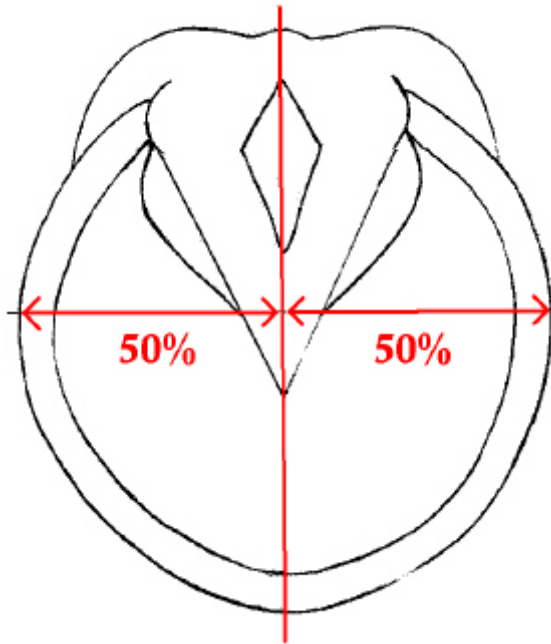


Figure 2: Study #1 on medial-lateral balance.

It is typical of farriery books and articles to speak of ‘balance’ and symmetry. One often-cited measure of this is from the solar aspect, where it is commonly stated that the foot should be symmetric about the centerline of the frog (see figure 2).

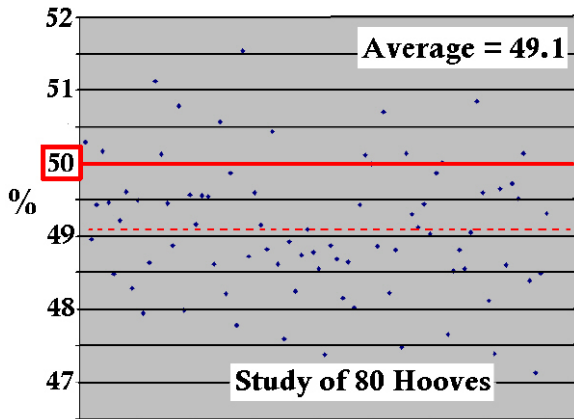


Figure 3: 66 of the 80 hooves measured display a narrower medial side.

However, from the dorsal aspect, the medial wall is generally steeper than the lateral, as many practitioners seem aware. This inherent asymmetry translates into the solar aspect and

takes the form that the distance from the ‘frog centerline’ to the medial wall is generally shorter than from the centerline to the lateral wall.

On average, the hoof is narrower to the medial side. Figure 3 shows the results of our study: 66 of the 80 hooves measured showed a narrower medial side. It is not a large amount, our average being that 49% of the width at the widest part of the hoof is the medial side. We will again touch on this asymmetry in our “study #6” presented later in this paper.

The asymmetry is not large, but in our opinion a farrier should not (for example) rasp the lateral wall, thinning it, in order to achieve perfect symmetry so often mentioned in books and articles.

Study #2. Hoof-Angle Related to Heel-Angle

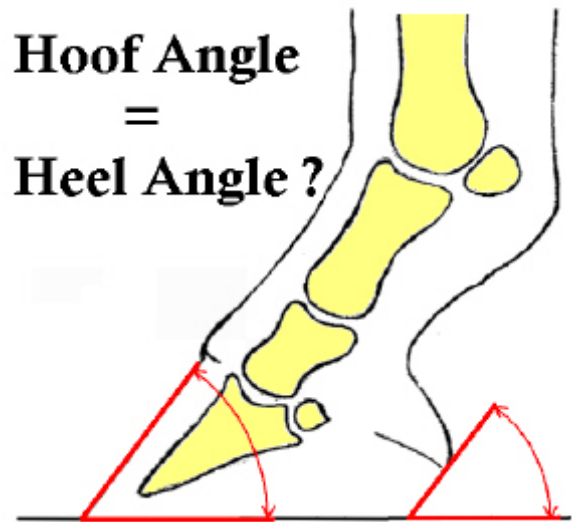


Figure 4: Study #2 on the often-stated goal of hoof-angle equaling heel-angle

There seems to be universal agreement in the literature³ that from the lateral aspect the hoof and heel should ideally be parallel. That is, that the hoof-angle (measured from the dorsal hoof wall to the ground) should equal the heel-angle (measured from the wall at the heel to ground).

From our study of 230 hooves, we show the difference between hoof-angle and heel-angle in

the plot of figure 5. If the angles were equal, the values would cluster around zero on this graph. But we find the mean to be about 8.3 degrees – meaning the heel-angle is generally not as inclined as the hoof-angle. The standard deviation in the data was 8.4 degrees.

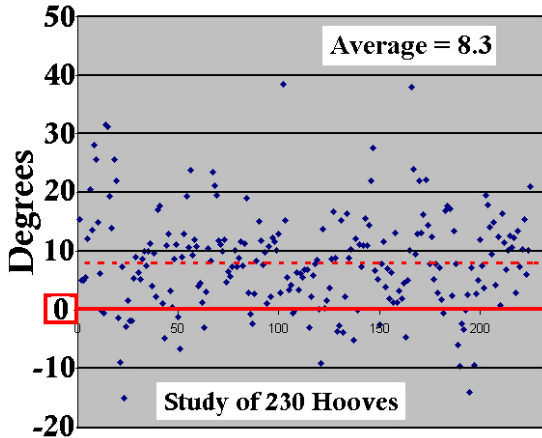


Figure 5: The hoof-angle minus the heel-angle for 230 hooves. The mean is not zero.

Hence, it is our belief that if the difference between hoof and heel angles is as much as 10 degrees, it is not an abnormal situation. In such cases, neither special trimming styles nor shoeing contraptions need be employed as an attempted remedy.

Study #3. Location of the Coffin-Joint Axis from the Lateral Aspect

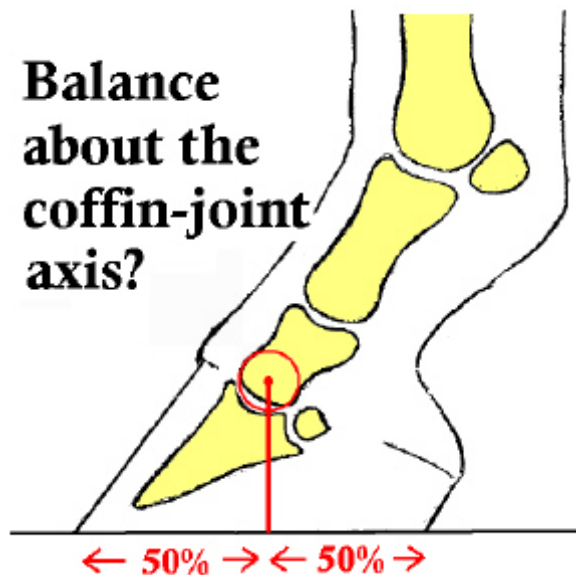


Figure 6: Study #3 on the notion depicted here of ideal dorso-palmar ‘balance’.

In this study, we looked at the position of the center of articulation of the coffin-joint with regard to the support length of the foot. As shown in figure 7, dropping a perpendicular line down from the coffin-joint’s center of articulation (COA), we computed the distance from this point to the toe as a percent of the length from toe to heel at the ground level. In the case of figure 7, we find that 68.9% of the support lies ahead of the center of articulation.

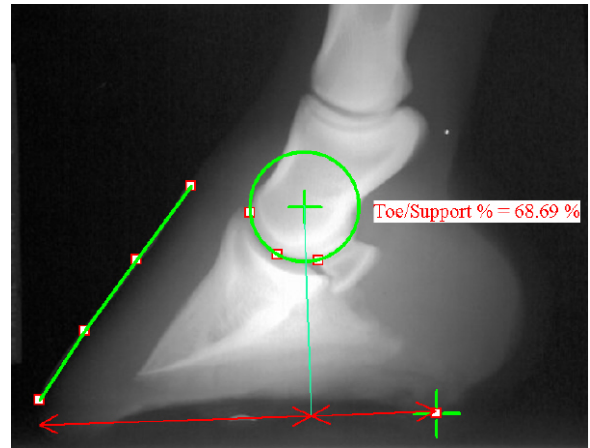


Figure 7 The “Toe/Support %” measures the percentage of the foot’s support that is “ahead of” the coffin-joints center of articulation (COA).

Our study used data from front feet only. A recent publication⁴ (among others) suggests that this percentage is ideally 50%, but the data in our study do not support this, with the average found for 131 hooves as 67.06 percent with a standard deviation of 5.41 percent. Hence the 50% point lies about 3 standard deviations away from the mean! For example, the digit shown in figure 7 would be very close to “normal” in our study. Figure 8 shows the data, with the average shown as a dashed line. Note that we found no hoof which displayed the 50% ‘balance’.

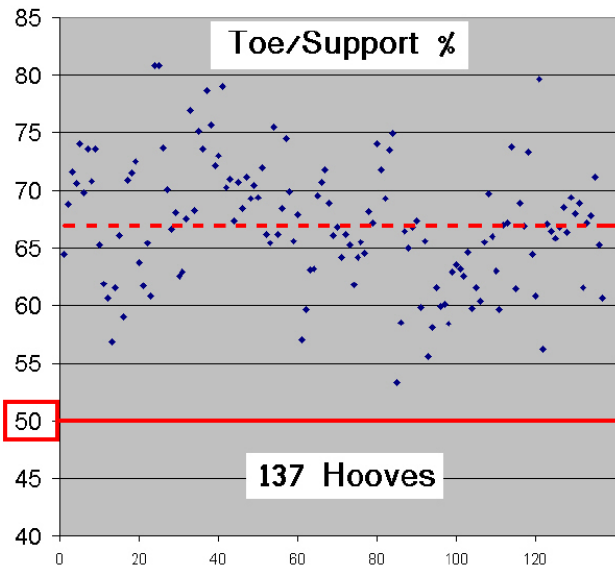


Figure 8 The “Toe/Support %” is the percentage of the ground support line that is forward of the coffin-joints center of articulation as viewed in a lateral radiograph. Our study was of front feet only.

Study #4. The Alignment of the Distal Phalanges

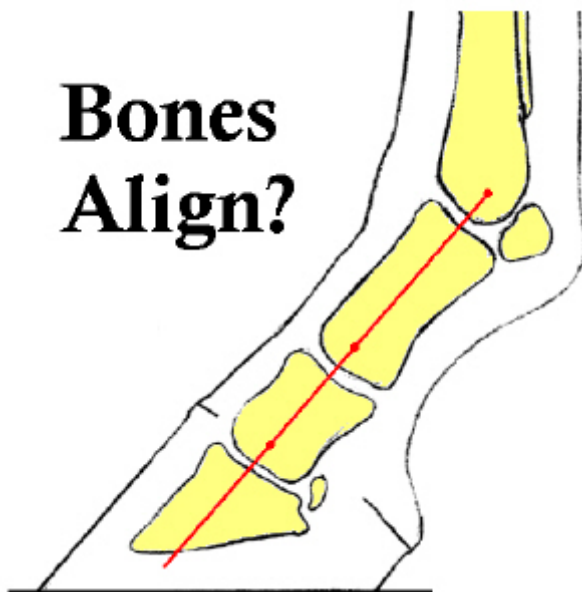


Figure 9: Study #4 – Almost universally there is a belief that the distal phalanges should “line up” as indicated in this cartoon.

Regarding the coffin and pastern joint angles as measured in figure 1, there is an oft-quoted

“rule of thumb” that these angles should be near zero for good bone alignment³. Using the method of measuring developed in this paper provides a way to study a population of horses and see if these angles are typically near zero. We measured the lateral radiographs of 151 hooves and found that the average coffin-joint angle is 8.27 degrees (with a standard deviation of 9.04 degrees), and the average pastern-joint angle is 5.78 degrees (with a standard deviation of 5.18 degrees).

These numeric results mean that the bones do not align in a straight line, but are slightly more ‘upright’ than that. Of course, this data is dependent on how the horse was stood during radiography, shoeing details, and other influences. We believe these other influences explain the high standard deviations in the data. Generally we tried to have both feet on equal height blocks and stand the horse with the cannon bone vertical. It is our opinion that our study is representative, and that a similar study on any group of horses would show that the “perfect alignment” of the bones so often shown in farrier publications is not reflective of how horses are conformed.

Figures 10 and 11 show the data from our study, with the “zero” degree (aligned) position marked with a heavy line, and the average marked with a dashed line.

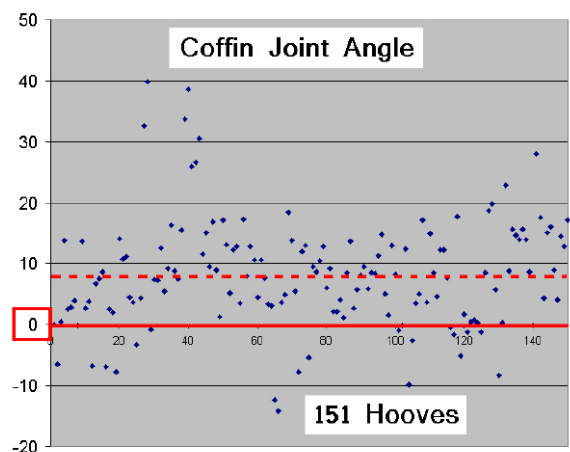


Figure 10 The average coffin-joint angle was 8.27 degrees (dashed line) with a standard deviation of 9.04 degrees.

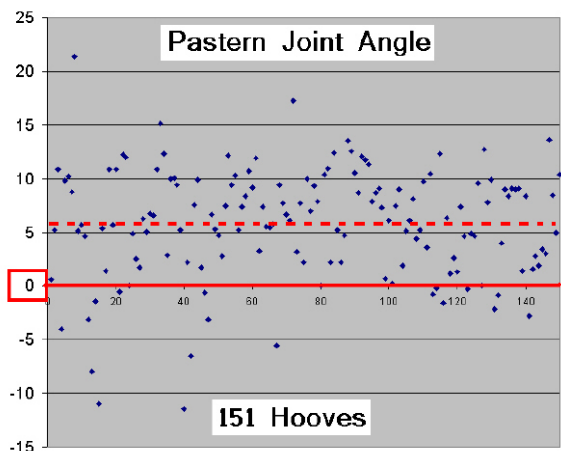


Figure 11 The average pastern-joint angle was 5.78 degrees (dashed line) with a standard deviation of 5.18 degrees.

Study #5. Medial-Lateral ‘Balance’ as Judged from the DP Radiograph

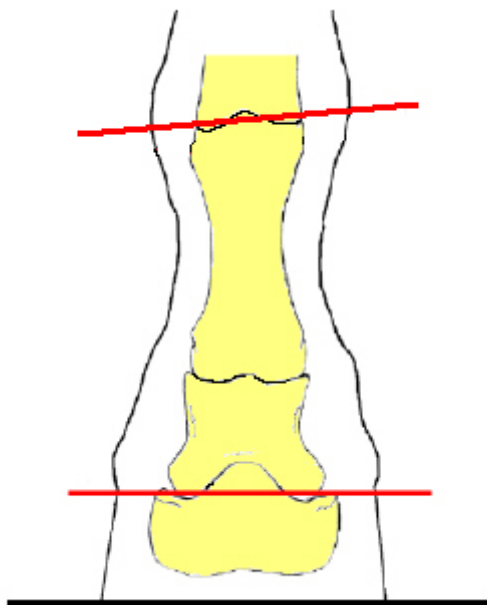


Figure 12: Study #5 – It is generally accepted that the coffin-joint’s axis should be parallel to ground for proper ‘medial-lateral balance’.

Some practitioners measure the distance from the underside of P3 to the ground (in an DP radiograph) on both the lateral and medial side in order to judge medial-lateral balance of the hoof. We have found it advantageous to instead

measure the angle (relative to ground) formed by a line which is aligned with the axis of the coffin-joint. We find that picking key points on the distal end of P2 to find the coffin-joint axis is more reliable than attempting measures on the underside of P3 in DP radiographs. The palmar surface of P3 as imaged in DP radiographs is often fuzzy, highly dependent on the relative angle of the foot and the x-ray source, and hence prone to error. In any case, from a biomechanical view-point, one can argue that what really matters is the orientation of the coffin-joint’s axis of rotation.

In this study we measured, in the horizontal DP radiograph, the angular deviation between the coffin-joint’s axis and the fetlock-joint’s axis. Most horses in the study were trimmed so that the coffin-joint was approximately parallel to ground. What was seen in the study was that the fetlock-joint was generally tilted relative to ground with the lateral side of the joint lower (towards the ground). This is depicted in the cartoon of figure 12. Leaving the trim out of the analysis was then done by measuring the angular misalignment of the coffin-joint’s axis and the fetlock-joint’s axis. In a study of 34 hooves, all 34 showed this “tilt to the lateral side” as depicted in figure 12. The source of this tilt is the P1 bone which has an asymmetry such that the proximal end (at the fetlock joint) is generally between 1.5 and 4.5 degrees tilted relative to the distal end (at the pastern joint).

We point out this asymmetry and just to raise awareness -- it has certainly been noted before^b (and others). We ask: why should it be so widely accepted that the coffin-joint be parallel to ground, when this practice ensures the fetlock-joint will *not* be parallel to ground? Perhaps the hoof should be trimmed, by dropping the medial heel more so than today’s practice, so that we ‘split the difference’ and have the coffin and fetlock joints both similarly misaligned relative to ground. At present we still promote attempting to trim for ‘coffin-joint parallel to ground’ but we have come to feel that it is perhaps better to err on the side of medial-heel being lower, rather than the opposite.

Study #6. Relating the Tip of the Frog to a Location on the P3 Bone

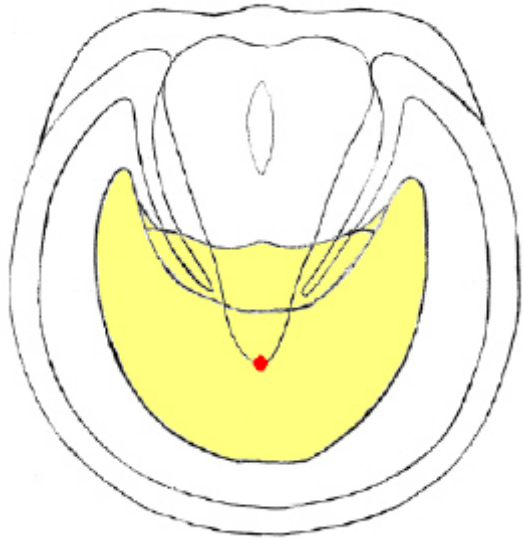


Figure 13: Study #6 – the tip of the frog is used as a reference point in many schemes. How constant is this point with respect to the coffin bone?

Numerous schemes employed in farriery rely on locating the tip of the frog as a sort of geometric marker. If one adopts the viewpoint that what matters is where the internal bones are located, this naturally raises the question of how well the tip of the frog corresponds to a fixed point on the P3 bone.

In conjunction with farrier and hoof researcher Michael T. Savoldi, we are undertaking a study of this relationship. Cadaver legs are dissected and the bones removed and cleaned for a later digital photographic and measurement study. After cleaning the tip of the frog, a hole is carefully drilled, perpendicular to the plane of the sole, and into the P3 bone. After removing the sole, a second hole is drilled at the tip of the “live frog”, an internal sensitive structure. Later, when the P3 bone is removed and cleaned, it is photographed from the palmar aspect and displays these two drilled holes.

We then establish a geometry on the palmar aspect of P3 by means of a mathematical fit of a “3-parameter ellipse” (an ellipse which is allowed to be ‘lop-sided’ with two differing

values for it’s minor-axis). We have found this geometric shape fits the P3 bone quite well, as again, it shows an asymmetry: it is generally narrower to the medial side than to the lateral side. In our study, 26 of the 31 bones showed this asymmetry with a narrower medial side.

Using the major and minor axes of the numerically-fit 3-parameter ellipse to establish a reference coordinate system on the bone, we could then measure the locations of the two holes and quantify the results. Before publishing the full details of this quantification, we wish to complete our study which will be of over 100 pedal bones. Here, we only show results from 31 bones in figure 14. The figure indicates the ‘scatter’ of these points on the P3 bone. A future publication, when we have completed measurements on 100 bones will give the statistics of the ‘scatter’ more fully.

Figure 14 indicates that the tip of the external frog varies more in the dorso-palmar axis than in the medial-lateral axis. It also shows that it may vary by more than 1.27 cm (0.5 inch) for an average sized hoof. Hence, it may be a reasonable external marker, but is by no means a perfect landmark.

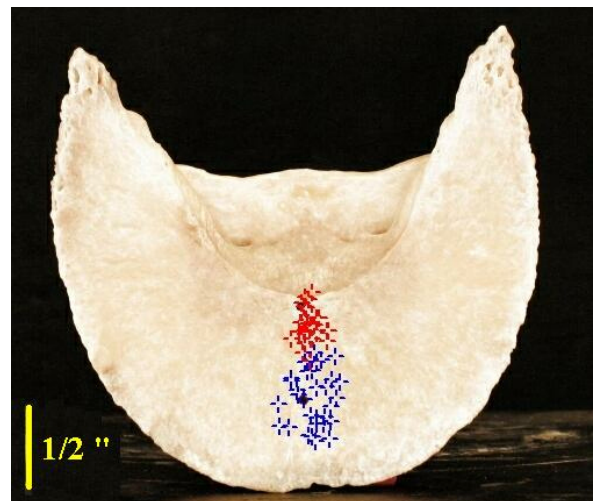


Figure 14: The red points represent location of the tip of the ‘live frog’ and the blue points represent the tip of the ‘external frog’. These points (from 31 bones) have all been mapped ratio-metrically onto one image for visualization.

Study #7. Relating the Widest Part of the Foot to the Coffin-Joint Location

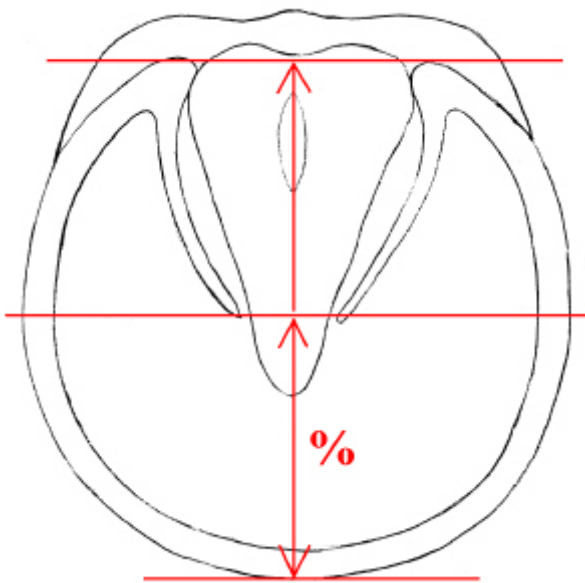


Figure 15: The location of the widest-part of the foot is compared with the data from Study #3 to relate the widest part of the foot to the location of the coffin-joint center of articulation.

In this study, photographs of the solar aspect of 160 front hooves were measured to compute the percentage of the foot which is ahead of the widest part of the foot as viewed from this aspect.

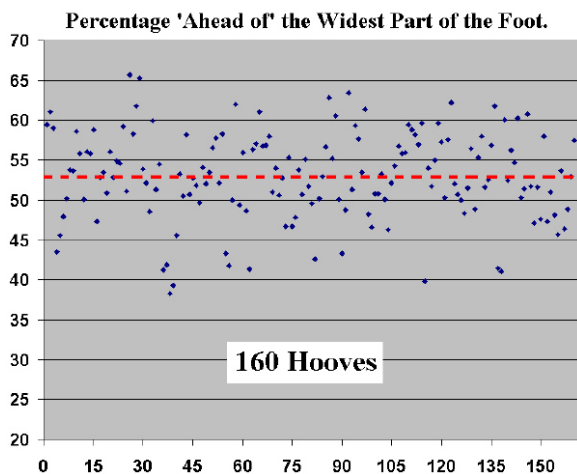


Figure 16: The percentage of the foot support (on hard horn) which is 'ahead of' the widest part of the foot. This data is for front feet only.

For our study, we measure from the heel-points where the hard horn contacts the ground up to the toe. Indeed, the most caudal portion of the frog may form a portion of the weight-bearing surface and may extend further back (caudally) from these heel points, but we find it difficult to reliably identify the location of the most caudal support afforded by the frog, and so did not attempt to measure the frog's contribution. This corresponds exactly to the method used in measuring in lateral radiographs in our Study#3. In our group, the average portion of the foot ahead of the widest part of the foot was 53.0% with a standard deviation of 5.5%. The data is shown in figure 16.

Comparing these results with those of study #3 shows that, on average, the center of articulation of the coffin-joint lies 14% more caudally than the widest part of the foot. For an average size foot with a support length of 12.7 cm (5.0 inch), the center of articulation is on average 1.8 cm (0.7 inch) further back than the widest part of the foot.

Discussion

The prevalent notions so often cited in books and articles regarding the hoof (and the bone placement within) should at best be considered 'rules of thumb'. In most cases, one sees that they represent the 'general structure' of the situation. A farrier, in the field, has many things to be concerned with, and following these rules of thumb is not unreasonable. But given today's digital cameras, digital radiograph systems, and computer measurement software, we can -- and should -- take a closer look. When we take this closer look, we find that there are obvious trends to the data. Whereas it seems to be human nature to expect that things are "split 50-50" or are "aligned in parallel" or "align in a straight line", the reality of biological systems is that small-to-moderate asymmetries are present. It is our belief that we should aspire to "get to the next level" of precision in these matters, rather than continuing to quote ingrained beliefs which are, at best, rough summaries of reality.

References and Footnotes

1. Craig, J., Craig, M., and Weltner, T. Quantifying Conformation of the Equine Digit from Lateromedial Radiographs, in *Proceedings of the 21st Annual AESM Conference*, Sacramento, CA, Sept. 2001. Available at www.eponatech.com .

2. Craig, J., Craig, M., Savoldi, M. and Waldsmith, J., Rotation Centers of the Equine Digit and their Use in Quantifying Conformation, presented at the Roth Kinematics Symposium, Stanford University, June 21, 2003. Available at www.eponatech.com .

3. Stashak, T.S. Adams' Lameness in Horses, 5th Edition, Lippincott Williams & Wilkens, 2002, page 1091.

4. Williams, G, and Deacon, M., No Hoof, No Horse, London: The Kenilworth Press Ltd, 1999, Figure 3.1

^a Metron, EponaTech, P.O. Box 361, Creston, CA 93432, USA. www.eponatech.com

^b Parks, A., *Equine Lower Limb Anatomy*, a talk given at the 2nd International Hoof Summit, Cincinnati, Ohio, February, 2005.