

*This article originally appeared in the American Farrier's Journal June/July 2007 and also in the European Farrier's Journal No. 126, 2007.*

## **Tracking a Founder Case over Five Years**

**Monique Craig**

[www.eponashoe.com](http://www.eponashoe.com)

Although I first heard about this founder case in December 2001, I was not able to help until February of 2002. I ended up adopting 'Refreshing Pause' (a.k.a. 'RP') eight months later and she stayed with us for almost 4 years until she was euthanized in August 2006 at the age of 23. RP had foundered in early Spring 2001 after foaling, due to retained placenta. She had raced till the age of three and was retired as a broodmare due to a racetrack injury (she broke her left leg at the track).



'Refreshing Pause' in 2006.

I was called to help this mare as a last resort. RP was a week away from being put down when I started to get involved with her case. I started to work on RP in February of 2002. The radiographs did not look good but it was nothing compared to the state of her hooves. RP's entire hoof capsules were practically dead. Large pieces of wall came off in my hands as I touched the hooves! The situation looked even worse when I looked at her soles. They were thin, weak and very 'dropped'. At one point I started to wonder what I had gotten myself into! I heard that a couple other farriers had declined to work on this case. I managed somehow to glue composite shoes on her hooves. I was not very optimistic about the outcome of my shoeing. When I started to work on this mare she could barely stand.



Figure 1. RP in February of 2002.

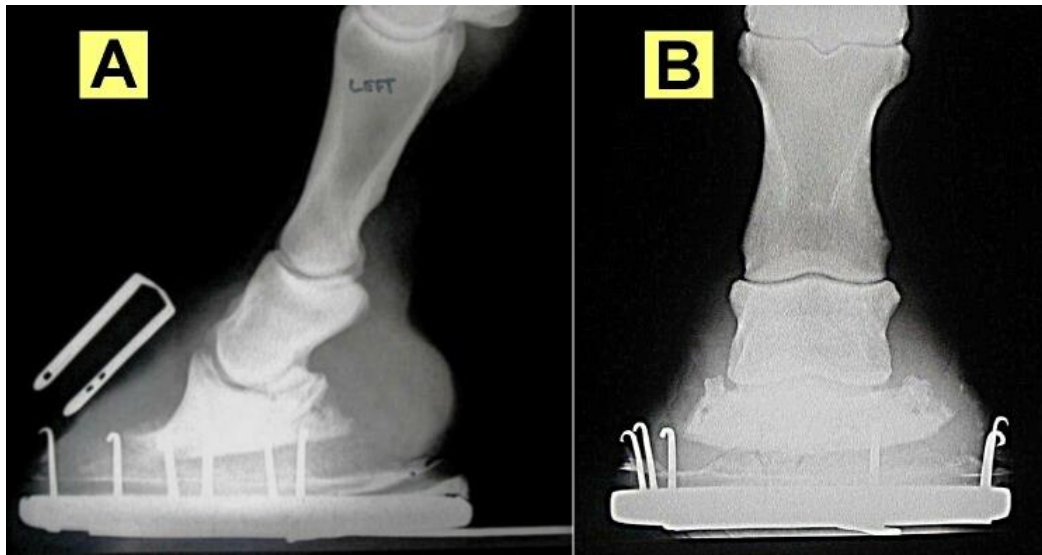


Figure 2: Radiographs of RP's left fore in 2002.

The first couple of shoeings did not significantly improve the health of the hooves but RP was comfortable enough to be brought back to her pasture. Beginning in May 2002, things started to look up. I was actually pleasantly surprised by the outcome. Her right hoof looked quite decent and despite the shape of her left hoof she was actually capable of standing on it without shoe and without drugs (fig.3)



Figure 3: Glue-on shoe in May of 2002. It seemed the only way to deal with her hoof at that time. Image 'A' shows hoof before glue-on shoe applied (shown in 'B'). It was also a challenge to provide proper support to the digit without putting excessive pressure at the sole. It was also a challenge to apply the shoe and glue without tipping the hoof capsule to the medial or lateral side.

RP was coming along fine till September of that year. It was about that time that I temporarily lost touch with this mare. Then, in late October, the ranch manager asked me if I wanted to adopt her. She had been a brood mare, but now breeding RP was too risky. The owner was faced with either putting her down or finding a home! I felt that it was unfair to put her down at this stage since she had resumed a 'regular' horse life. RP was delivered to my home in a pretty deplorable state. She had dropped weight significantly and she was overdue for shoeing. RP's weight loss was not a case of neglect but I think more due to stress. RP was separated from her pasture friends and moved to a stall for weeks. After that brief period, I never managed to keep her in a stall – she wanted out! She lived at our ranch in a large covered pen during the night with horses next to her. After a couple of months at my place, RP made a full recovery back to her normal weight.



Figure 4: RP's left fore in 2003.

RP was healthy and strong enough to be in a pasture but I was not comfortable with putting her with my young warmblood mares. I let RP have her own pasture. This did not work, RP hated being alone and made it very clear by pawing very large holes by her

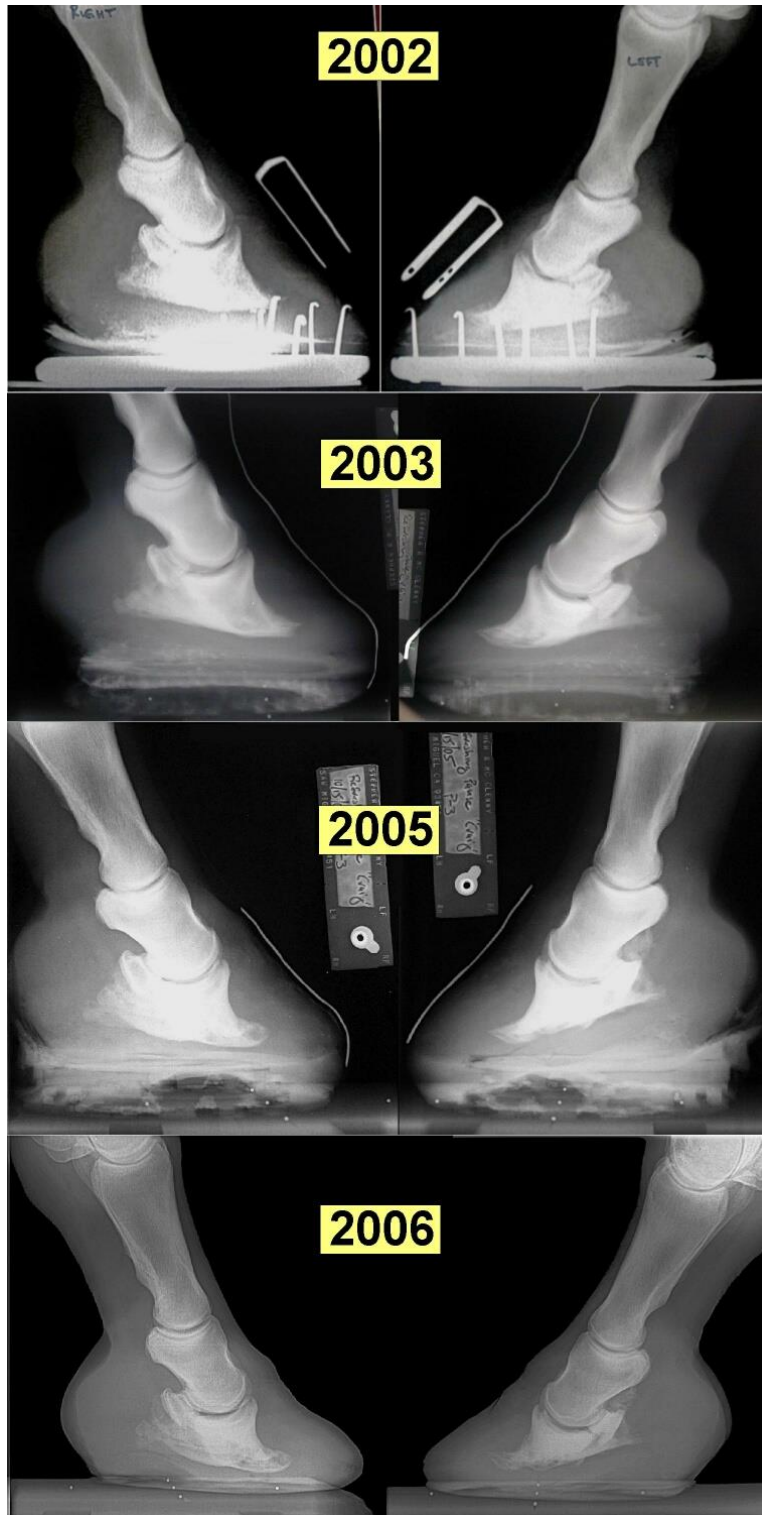

Figure 5: Radiographs of RP's feet over several years.  
All the x-rays were taken prior to shoeing.

pasture gate. I finally gave in and let her loose on our ranch. This way she could visit other horses without being hurt. She immediately took up a very busy social life. She loved it and never was a nuisance. She roamed our 40 acre property loose during the day for nearly four years. Most of the year our ground is very dry and hard.

By late Fall 2005, RP showed signs of slowing down, she started to become stiff in the rear, especially after spending the night in her pen. She always got better after she moved on the ranch. It is not unusual for older horses to get stiff with age but in RP's case it was very worrisome since her pedal bones were already badly damaged. She never exhibited the classic 'founder stance' but her old-age stiffness in the rear caused her to start compensating and loading harder on her front hooves. We took radiographs of her hocks around this time, and they looked reasonably clean for her age. Her stiffness seemed to come from her hips. The lateral radiographs of her front hooves taken in October 2005 (fig.5) showed signs of further deterioration of the front pedal bones. Amazingly, despite her damaged pedal bones, she was still incredibly active.

If you look at the progression of images in figure 3, you see that she was somewhat better balanced in the earlier years. As her rear end stiffness began affecting her loading, she was tending to bear more weight on the left foot, and somewhat less on the right. This caused the left heel to grow faster, and I found I had to shoe more often (about every 4 weeks) to try to keep things balanced. Despite all efforts, she was tending to flatten her left foot (and very little sole) and become more upright on her right foot.

Early Spring 2006 marked the beginning of the end for RP. We had a cold spell with two inches of snow - a rare event for our area! She suffered a mild founder episode after that cold spell. By April she was back roaming on our ranch but this time she could

no longer trot or run. Her radiographs looked worse than ever, and I knew that her days were numbered. My veterinarian and I decided to let her enjoy one last summer. I rarely had to administer pain medication to RP but after her last episode of founder I kept her on medication daily (2 grams of bute). In July 2006, we had a heat wave and the temperature reached 113 Fahrenheit for almost a week. RP started to decline in earnest after that. She would no longer leave her pen to roam our property. RP kept standing but I knew that she was in pain. I finally let her go in August 2006.

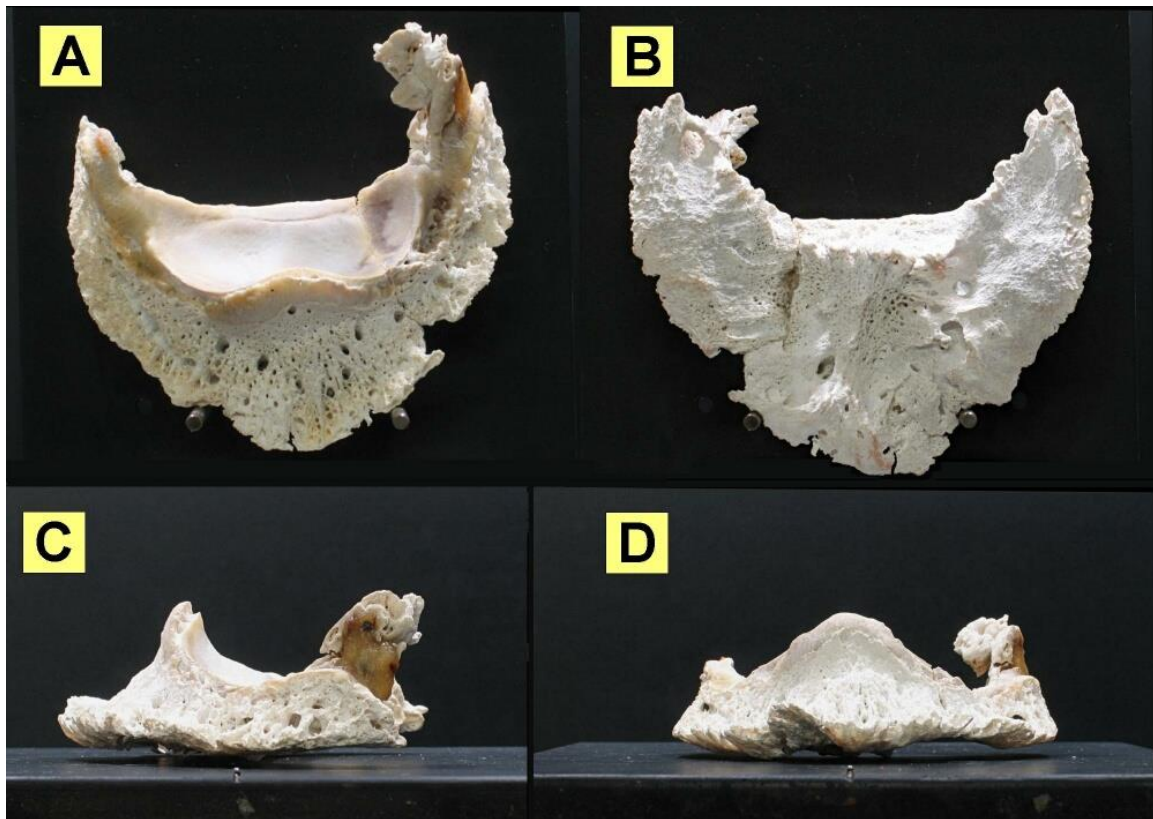


Figure 6: The pedal bone from RP's left fore. RP front legs were harvested after euthanizing her. Mike Savoldi and I have the entire dissection series.

RP was never diagnosed with nor showed signs of insulin resistance. RP was never completely comfortable when large

fluctuations in temperatures occurred. I have noticed in RP's case and other serious founder cases, hooves would become painful when temperature changes occur abruptly or become extreme. I feel that this sensitivity to temperature is related to the damage that occurred at the sensitive lamina during her initial founder episode. The laminae can heal but not necessarily regain their original structure. The complex system of micro vessels passing through the sensitive laminae also gets damaged. The sensitive laminae contain a very complex system of micro vessels called 'arteriovenous anastomoses' – a network of interconnections between small arteries, called 'arterioles' and small veins, called 'venules'. The arterioles and venules are connected by shunts called 'arterio-venous shunts'. When these shunts are open, they allow the blood to move directly between the arterioles and venules, thus by-passing the capillary bed. This system helps maximize the peripheral blood flow during vasodilation. After a serious founder episode, the laminae and the micro vessels become permanently damaged. This system of micro vessels brings oxygen and nutrients to, and removes waste from, the sensitive laminae; but also plays a very important role in thermoregulation [1]. Obviously any permanent damage to these vessels will impair proper thermoregulation of the hoof.

Badly remodeled pedal bones are very hard to support. The load at the pedal bone is no longer shared smoothly and evenly across the bone, connective tissues, and sole, but becomes locally concentrated in certain areas. Figure 2B shows that when we first met RP her pedal bone was already remodeled such that the outer rim at the periphery of the bone was missing and 'turned up'. Figure 3A shows how the sole is taking on the shape of this remodeled bone. This adds stress to the sole dermis. Dermis damage at the sole will not allow for good production of keratin. The pedal bone will start sinking. It is crucial in such founder cases to provide adequate sole and arch support in order to stabilize and share the load at the bottom of hoof. I will hope to give more

details on how to achieve this in another article. In the meantime, my advice is to be very 'zen' with the sole – leave all you can -- when you encounter problems like this.

Although, I had to eventually put down RP, I feel that I gave her a few years of quality life. I helped her be comfortable for several years beyond my initial estimates. However, even with flexible shoes and multi layers of high tech packing material, there are limits with helping in such a situation. RP was an active horse and eventually, it came to a point where there was not much I could do to support her badly damage pedal bones. I always got a kick out of the reaction of a new veterinarian taking her radiographs – the foot didn't look so bad from the outside, and she moved OK, but when the veterinarian saw the radiographs it was a real surprise for them!

I don't suggest keeping all such horrific founder cases if the horse is not happy – you can see it in their eyes. In the case of RP, anyone that met her could see that she was really happy, had a fighting spirit, and wanted to keep going as long as possible.

## References

[1] "Equine Laminitis", Chris Pollitt, A report for the Rural Industries Research and Development Corporation, November 2001.